

TABLE 2.2 Examples of Singular and Plural Forms of Body Terminology

Singular ending	Plural ending	Examples
-a	-ae	Papilla, papillae; axilla, axillae
-en	-ina	Foramen, foramina; lumen, lumina
-ex	-ices	Cortex, cortices
-is	-es	Testis, testes
-is	-ides	Epididymis, epididymides
-ix	-ices	Matrix, matrices; appendix, appendices
-on	-a	Mitochondrion, mitochondria
-um	-a	Epithelium, epithelia; cilium, cilia; ovum, ova
-us	-i	Humerus, humeri; carpus, carpi; fasciculus, fasciculi
-us	-ora	Corpus, corpora
-x	-ges	Phalanx, phalanges; pharynx, pharynges
-y	-ies	Artery, arteries; ovary, ovaries

PLANES OF REFERENCE AND DESCRIPTIVE TERMINOLOGY

All of the descriptive planes of reference and terms of direction used in anatomy are standardized because of their reference to the body in anatomical position.

Objective 8 Identify the planes of reference used to locate structures within the body.

Objective 9 Describe the anatomical position.

Objective 10 Define and be able to properly use the descriptive and directional terms that refer to the body.

Planes of Reference

In order to visualize and study the structural arrangements of various organs, the body may be sectioned (cut) and diagrammed according to three fundamental planes of reference: a **sagittal (saj'i-tal) plane**, a **coronal plane**, and a **transverse plane** (figs. 2.11 and 2.12). A sagittal plane extends vertically through the body dividing it into right and left portions. A *midsagittal (median) plane* is a sagittal plane that passes lengthwise through the midplane of the body, dividing it equally into right and left halves. Coronal, or *frontal*, planes also pass lengthwise and divide the body

coronal: L. *corona*, crown

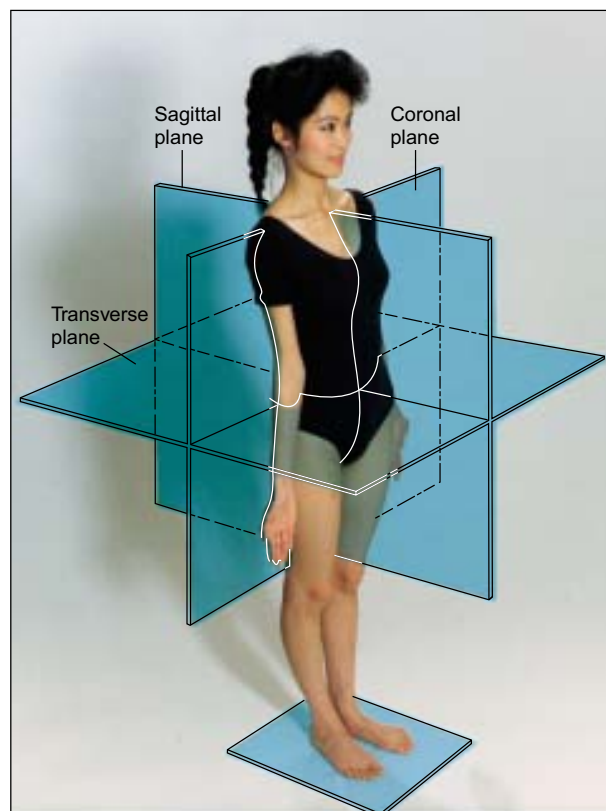


FIGURE 2.11 Planes of reference through the body.

into anterior (front) and posterior (back) portions. Transverse planes, also called *horizontal*, or *cross-sectional*, planes, divide the body into superior (upper) and inferior (lower) portions.

The value of the computerized tomographic X-ray (CT) scan (see fig. 1.19a) is that it displays an image along a transverse plane similar to that which could otherwise be obtained only in an actual section through the body. Prior to the development of this technique, the vertical plane of conventional radiographs made it difficult, if not impossible, to assess the extent of body irregularities.

Descriptive Terminology

Anatomical Position

All terms of direction that describe the relationship of one body part to another are made in reference to the **anatomical position**. In the anatomical position, the body is erect, the feet are parallel to each other and flat on the floor, the eyes are directed forward, and the arms are at the sides of the body with the palms of the hands turned forward and the fingers pointed straight down (fig. 2.13).

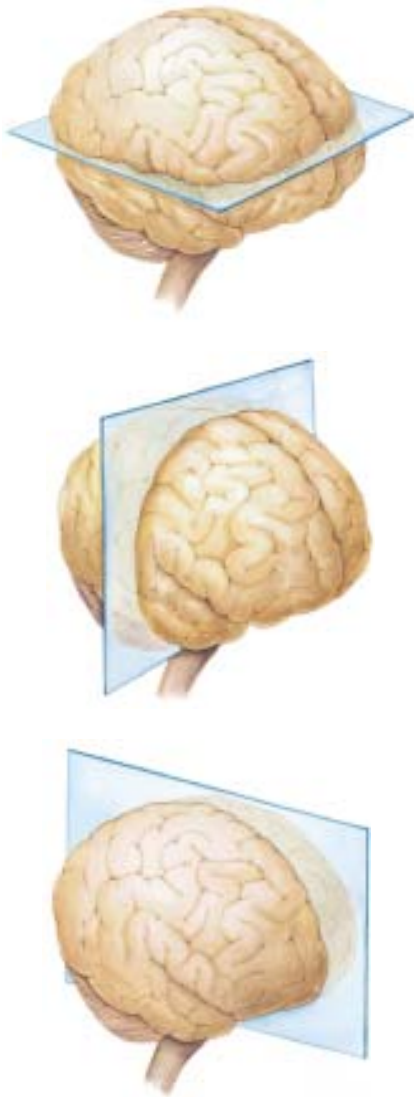


FIGURE 2.12 The human brain sectioned along (a) a transverse plane, (b) a coronal plane, and (c) a sagittal plane.

Directional Terms

Directional terms are used to locate structures and regions of the body relative to the anatomical position. A summary of directional terms is presented in table 2.3.

Clinical Procedures

Certain clinical procedures are important in determining anatomical structure and function in a living individual. The most common of these are as follows:

- **Inspection.** Visually observing the body to note any clinical symptoms, such as abnormal skin color, swelling, or rashes. Other observations may include needle marks on the skin, irregular breathing rates, or abnormal behavior.



FIGURE 2.13 In the anatomical position, the body is erect, the feet parallel, the eyes directed forward, the arms to the sides with the palms directed forward, and the fingers pointed straight down.

- **Palpation.** Applying the fingers with firm pressure to the surface of the body to feel surface landmarks, lumps, tender spots, or pulsations.
- **Percussion.** Tapping sharply on various locations on the thorax or abdomen to detect resonating vibrations as an aid in locating excess fluids or organ abnormalities.
- **Auscultation.** Listening to the sounds that various organs make (breathing, heartbeat, digestive sounds, and so forth).
- **Reflex testing.** Observing a person's automatic (involuntary) response to a stimulus. One test of a reflex mechanism involves tapping a predetermined tendon with a reflex hammer and noting the response.

✓ Knowledge Check

9. Explain why a transverse plane through an organ is more important in studying specific systems than a transverse plane through the body.
10. What do we mean when we say that directional terms are relative and must be used in reference to a body structure or a body in anatomical position?